



PATIENT PRESENTING CLINICAL SIGNS

Pi Thorsten History: Abnormal behavior – stuck in corner, only eats if food is presented.

SPECIES Physical Examination: Hyperemic mucus membranes.

Canine Urinalysis: N/A.

CBC: Neutrophilia.

BREED Serum Biochemistry: N/A.

Husky Mix Radiographic Findings: N/A.

SEX ULTRASONOGRAPHIC EXAMINATION OF THE ABDOMEN

MN **Urinary System**

Age Full urinary bladder with a normal thickness and appearance of the wall. Small amount of floating hyperechogenic sediment present. No uroliths evident.

WEIGHT Normal trigone area, proximal urethra, and iliac blood vessels.

35 kg Normal iliac lymph nodes. Ureters not visualized.

Normal renal size (both 6.7 cm), echogenic appearance, cortico-medullary differentiation, pelvis, and capsule.

INTERPRETED BY **Reproductive System**

Small hypoechogenic prostate.

Remo Lobetti, BVSc,
MMedVet (Med), PhD, Dipl.
ECVIM

Adrenal Glands

Normal position, echogenic appearance, shape, and size. Left 0.54 cm, right 0.57 cm.

IMAGING PERFORMED BY

Dr Sarah Barthelemy

Spleen

Normal size and echogenic appearance. Smooth homogenous parenchyma, regular curvilinear capsule, and normal vasculature. No evidence of inflammatory, neoplastic, infarction, or infiltrative changes noted.

HOSPITAL NAME

Crowchild Trail Veterinary
Clinic

REFERRING VET

Dr Rondot

Liver

Normal size, echogenic appearance, portal markings, and regular curvilinear capsule. No nodules or masses evident. Small gall bladder containing normal anechoic bile. Normal thickness and echogenic appearance of the gall bladder wall. Normal bile duct.

INVOICE

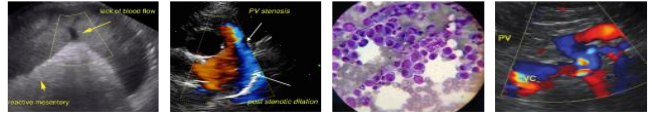
303788

Gastrointestinal

Normal appearance of the stomach, duodenum, small intestine, ileo-cecal junction, and colon with no loss of layering, normal wall thickness (jejunum 0.36 cm) and peristalsis, and no distension of the lumen. Ingesta within the stomach.

DATE

1/19/23

**PATIENT** *Pancreas*

Pi Thorsten Normal size (left 1.6 cm) and echogenic appearance. Regular capsule. Normal echogenic appearance of the mesentery and fat surrounding the pancreas.

SPECIES *Free Abdomen*

Canine No mesenteric lymphadenomegaly.
No ascites.

BREED

Husky Mix

ULTRASONOGRAPHIC FINDINGS**SEX** Primary Findings:

MN

- None.

Age

9 years

Secondary Findings:

- Urinary bladder sediment.

WEIGHT

35 kg

INTERPRETATION OF THE FINDINGS & FURTHER RECOMMENDATIONS

Normal ultrasound examination of the abdomen.

INTERPRETED BY

With the presenting clinical signs, intra-cranial disease would be highly likely.

Further assessment would be neurological examination and possibly MRI of the brain.

Remo Lobetti, BVSc,
MMedVet (Med), PhD, Dipl.
ECVIM

IMAGING PERFORMED BY

Dr Sarah Barthelemy

The information and recommendations provided are based on the images presented by the referring veterinarian. No evaluation can be communicated regarding pathology that was not visible in the image/video clips provided.

HOSPITAL NAME

Thank you for this referral. If the clinical or image interpretation does not parallel your findings or if I can be of any further assistance, please contact me.

Crowchild Trail Veterinary
Clinic

Remo Lobetti, BVSc, MMedVet (Med), PhD, Dipl. ECVIM (Internal Medicine)
rlobetti@mweb.co.za

REFERRING VET

Dr Rondot

INVOICE

303788

DATE

1/19/23